

MODIFIED OSTEOTOMY FOR REMOVAL OF ECTOPIC DENTAL UNIT RETAINED IN MANDIBLE: CASE REPORT

OSTEOTOMIA MODIFICADA PARA REMOÇÃO DE UNIDADE DENTÁRIA ECTÓPICA RETIDA NA MANDÍBULA: RELATO DE CASO

Albert Lubki Wagmacker - albertlubki@gmail.com

Dentist, Teixeira de Freitas, Bahia, Brasil.

Victoria Assunção Costa - victoria.assuncao2001@gmail.com

Dentist, Itamaraju, Bahia, Brasil.

Manuela Luanny Ventura Rocha - manurochs@gmail.com

Dentist at the Northeast Adventist University Teaching Center, Cachoeira, Bahia, Brasil.

Allan Israel Fortaleza Santos - allan.aifs@hotmail.com

Dentist at the Northeast Adventist University Teaching Center, Cachoeira, Bahia, Brasil.

Gilmar Rocha da Silva - gr.bucomaxilo@gmail.com

Oral and Maxillofacial Surgeon, Hospital Otorrinos, Feira de Santana, Bahia, Brasil.

Meily de Mello Sousa - meily.sousa2@gmail.com

Master in Public Health, professor at the Northeast Adventist University Teaching Center, Cachoeira, Bahia, Brasil.

Abstract: Introduction: Ectopic teeth are mostly discovered in routine radiographic examinations, their etiology is uncertain and little described in the literature. The ectopic lower molar is no exception to the rule of the others, its location can vary and can be found in: mandibular condyle, coronoid process and mandibular body. In these types of cases, you can choose to monitor or intervene. If surgical intervention is the treatment option and given the complexity of this type of tooth positioning, well-designed surgical planning is crucial, thus avoiding trans- and post-surgical complications. **Objective:** to report the clinical case of a modified osteotomy to remove an ectopic tooth unit retained in the mandible. **Case presentation:** male patient, 21 years old, sought the Oral and Maxillofacial Traumatology Clinic service at Hospital Otorrinos - Feira de Santana - Bahia to remove ectopic retained units 47 and 48. The surgical procedure was performed via intra-oral access in a hospital environment under general anesthesia. Use of piezoelectric for osteotomy and odontosection, and synthesis with autogenous and xenogeneic grafts together with titanium plates and screws. **Results:** The patient evolved without complications other than expected, such as controlled edema, trismus and paresthesia, which lasted only one week. **Conclusion:** individualized planning and the use of modern techniques enabled a better prognosis for the case.

Keywords: Molar, Third; Piezosurgery; Osteotomy; Bone Transplantation; Tooth, Unerupted.

INTRODUCTION

The morphological characteristics of the dental eruption They have an intimate connection with the biological factors of individuals, and those who have a "normality" profile, usually present Chronology and sequence of dental eruption considered standard, favoring the construction of a harmonious smile. ⁽¹⁾

The odontogenesis process is the result of Differentiation of oral epithelium cells and their interaction with adjacent tissues. However, due to pathological processes, developmental disorder, Trauma or iatrogeny, the dental elements that are in formation, may suffer changes in their characteristics, such as alteration of Position in the dental arch, thus changing the site of its eruption, or making it impossible. In some cases, the dental element(s) Ectopic(s) can be found in the palate region, maxillary sinus, mandibular condyle, coronoid process, mandibular body, orbital cavities and Nasal ⁽⁵⁾. According to research conducted on the subject, the incidence and prevalence of included teeth is higher in the third molar, representing about From 1% to 3% of the population. The second tooth that has the highest impact rate is the upper canine. ⁽⁸⁾

A significant part of these anomalies are asymptomatic, consequently most of the time are diagnosed by routine clinical and radiographic examinations. Thus, after the diagnosis of an ectopic tooth is possible to remain in proservation or intervene. If there is a need for intervention, and it is not carried out, it may lead to a series of problems, such as aesthetic, occlusal, TMJ dysfunctions, increased propensity to caries and periodontal diseases, dental sensitivity and complications During the surgical procedure. ⁽⁷⁾

There are several conducts for the treatment of this dental anomaly, however there are four suggested ways for the resolution of this Problematic, which may be: continuation of the unit when there are no symptoms, associated pathology or damage to the patient, orthodontic intervention for Eliminate dental impaction or the need to remove permanent/deciduous teeth, orthodontic therapy for unit repositioning Ectopic or extraction. ⁽⁶⁾

Within the scope of surgical interventions, most ectopic teeth may be associated with trans complications Surgical and postoperative, the most common can be: pain, paresthesia, infection, hemorrhage, iatrogenic damage in the adjacent unit and fracture Iatrogenic in the jaw. In addition, factors such as the ectopic position of the tooth, surgical technique, skill employed by the dental

surgeon (CD), materials Surgical, health status and age of the patient, can increase these risks and complications.⁽⁹⁾

The conduct for surgical tooth removal Ectopic consists of the blockade of nerve branches, incision and elevation of mucoperiosteal tissue, osteotomy, odontosection, elevation and avulsion of the unit Dental.⁽⁹⁾ Osteotomy can be done by the piezoelectric that has a characteristic called "selective cutting", enabling a Adequate visualization of the surgical field, absence of injuries to soft tissues, favoring less bleeding in the transoperative process. When Compared to rotary instruments, the piezoelectric has enabled a better tissue repair and preservation of noble structures, avoiding a possible Nerve and vessel injury.⁽¹⁰⁾

Injuries such as segmental defects of the jaw during the surgical trans can be temporarily stabilized through Titanium plates and screws. When titanium plates are used, along with microvascularized grafts, the success rates of the cases Increase, and thus represents the treatment of choice by the CD.⁽¹¹⁾

The design for the use of autogenous or xenogenic bone grafts is related to the recovery of bone height, thickness and Quality of bone tissue in places that require grafting. In this way, materials such as lyophilized and microvascularized grafts are being used Together with the surgical act of removing teeth to ensure a constitution of this fabric.⁽¹²⁾

Ectopic element surgeries need attention In the diagnosis, performing a responsible and efficient preoperative examination, in order to minimize any type of surgical complications. In addition, the Patients who will undergo tooth extractions should be guided about the risks and possibilities of such complications. Each case is unique and requires Proper planning. Therefore, the best choice technique is always the one that the CD is able to perform, has knowledge about it and is suitable for the case.

With this in mind, this work seeks to present A clinical case that explores these techniques, with a good postoperative result. This allows the expansion and dissemination of scientific works that Allow you to base the treatment decision of other CDs, enriching the literature on the subject.

CASE PRESENTATION

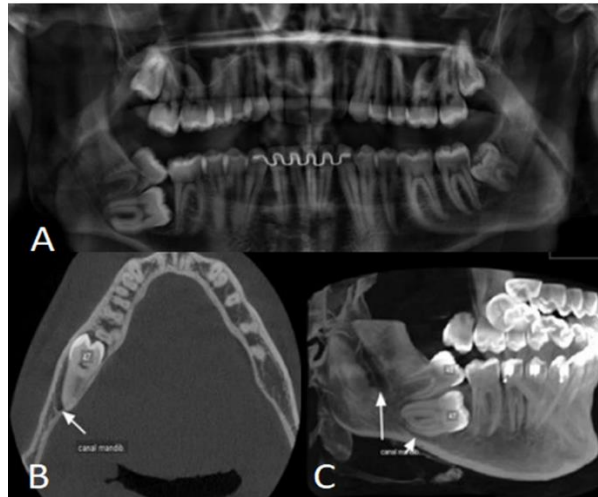
This case report had bioethical approval by the ethics and research committee (Opinion number: 6. 121,935) and has In order to report the case of a modified osteotomy for the removal of ectopic retained unit in the jaw, emphasizing relevant aspects for the Management of this change and the use of precise technologies such as piezoelectric surgery.

Patient M. R., 21 years old, male, Leucoderma, sought the Oral and Maxillofacial Clinic and Traumatology service of the Otorrinos Hospital - Feira de Santana - Bahia at the request of his orthodontist CD. During orthodontic treatment, it was identified through periapical radiography,

159

two dental units retained (47 and 48), making the Traction of unit 47, opting for extractions of the two units. Thus, after being referred, the patient did not report complaints of painful symptoms Or facial alteration.

Figure 1 - A- Panoramic x-ray showing units 47 and 48. B- Tomography cone beam showing element 47 in proximity to the mandibular canal. C- 3D Reconstruction



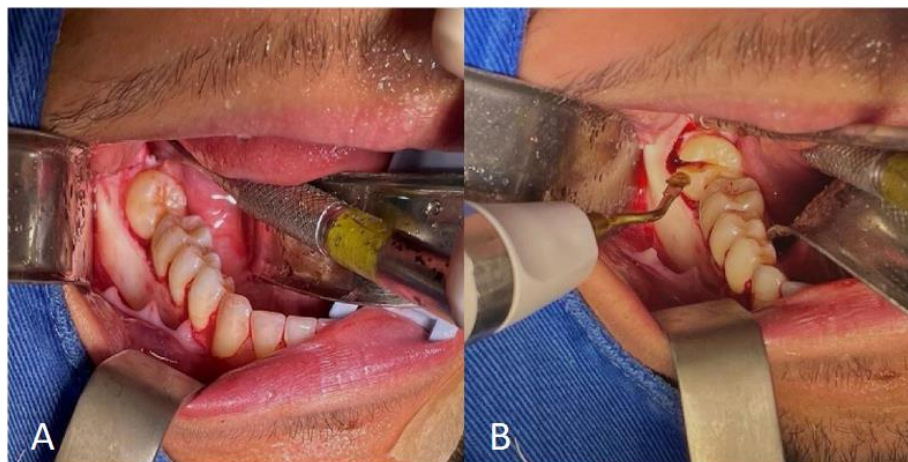
Source: Own Authorship, Cachoeira, 2023.

During the clinical examination, the patient does not report medication use, existence of systemic diseases, does not use alcohol and does not smoke, and the intraoral examination was noticed the absence of changes in soft tissue. During the performance of the odontogram, the absence of element 47 and element 48 in impacted mesioangular position was observed. Thus, imaging tests (panoramic radiography and cone beam computed tomography) were requested (Figure 1), in which it was possible to observe unit 47 retained in ectopic position in mandibular body region and element 48 classified as B-I according to Pell & Gregory (1933)

The proposed treatment was the surgical removal of units 47 and 48. The pre-, trans and post-surgical and the risks involved were clearly explained to the patient. After the proposal of the surgery, the Free and Informed Consent Term (TCLE) was read, agreed and signed. Preoperative tests were requested: complete blood count and coagulogram, pre-anesthetic evaluation with anesthesiologist. The patient was classified as ASA I, due to the absence of comorbidities.

The surgical procedure was performed by intra-oral access in a hospital environment under general anesthesia for better patient comfort, anxiety control and transsurgical stability. The patient was placed in dorsal decubitus, medicated with intravenous propofol and intubated orotracheally. Asepsis and extraoral antisepsis was performed with 2% chlorhexidine digluconate, application of sterile fields on the patient and installation of the oropharyngeal buffer.

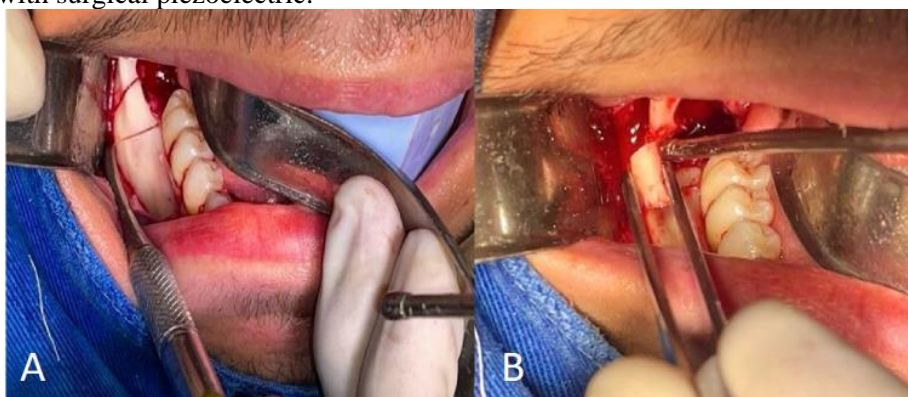Figure 2 - A- Mucoperiosteal detachment showing bone table. B- Odontosection performed with surgical piezoelectric.



Source: Own Authorship, Cachoeira, 2023).

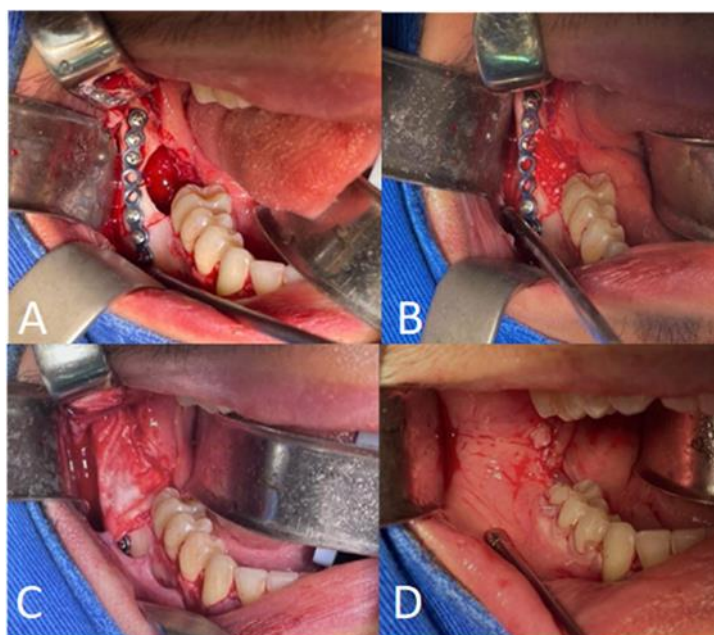
The local anesthetic of choice was Lidocaine 2% with Epinephrin 1:10000 (Xylestesin®) (Cristália®, Itapira, SP, Brazil) and the amount used 10ml (aspirated from an ampoule) with infiltration in the vestibular fornix region of the jaw with 10ml syringe with insulin needle, intrasulcular Neumann vestibular incision in the distal of unit 43 to unit 48 with scalpel no. 3 and blade n° 15, with mucoperiosteal detachment by vestibular until complete visualization of the bone tissue (Figure 2).

Figure 3 - A- Mucoperiosteal detachment showing bone table. B- Odontosection performed with surgical piezoelectric.



Source: Own Authorship, Cachoeira, 2023).

Figure 4 - A- Rigid plate fixation under autogenous graft. B- Filling the bone store with bovine graft. C- Coating of the bovine graft with collagen membrane. D- Interpapillary and continuous sutures



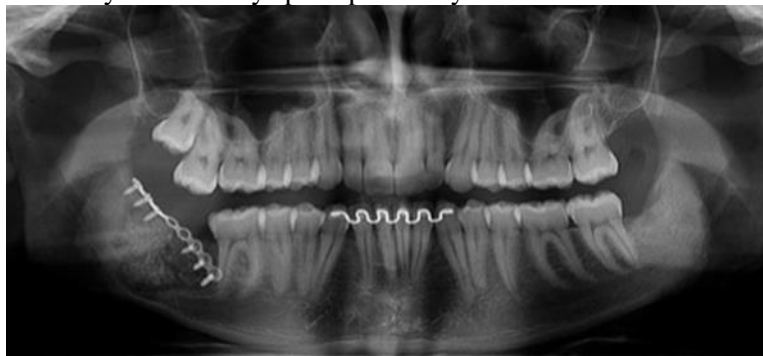
Source: Own Authorship, Cachoeira, 2023.

The osteotomy was performed by vestibular around element 48 followed by transverse odontosection in the vestibulolingual direction, Both with surgical piezoelectric. For extraction of the ectopic unit 47, a modified osteotomy was performed trapezoidal format with a smaller lower base (Figura 3).

The bone table was clamped and removed, immersed in physiological serum 0.9% for subsequent relocation as an autogenous graft. A Unit was removed from adapted sections. There was abundant irrigation with 0.9% physiological serum in the two bone stores. The stabilization of the jaw and Autogenous graft fixation was done with titanium plate with 08 holes, 2.0 system and 06 0.8mm screws of the same system due to imminent risk Of mandibular fracture. To fill the bone store was used graft with lyophilized bovine bone (Bio-oss[®]) (Geistlich Pharma AG[®], São Paulo, SP, Brazil) and collagen membrane (Bio-gide[®]) (Geistlich Pharma AG[®], São Paulo, SP, Brazil) (Figure 4).

Interpapillary sutures and suture were performed Continuous, in first intention with 4-0 suture thread (monocryl[®]) (Johnson & Johnson[®], São Paulo, SP, Brazil). Then, there was the removal of the oropharyngeal tampon, surgical fields and completion of the operation by the team. After the Procedure, all postoperative instructions were passed. Drug prescription was Amoxicillin 875mg of 12/12 hours for 07 days, Maxsulid 400mg of 12/12 hours for 05 days and Novalgina 1g of 06/06 hours for 03 days. The patient was discharged from the hospital on the same day, returning to the Office after 7 days. During return evaluation, no complications were reported in the postoperative period, the clinical aspect of the region Had tissue with healthy appearance, fully healed, without painful symptoms and without aesthetic and functional alteration. After 30 days it was Performed a new imaging examination through panoramic radiography and it was possible to notice signs suggestive of guided bone regeneration (ROG) through the Radiopaque area (Figure 5)

Figure 5 - Panoramic x-ray after 30 days postoperatively.



Source: Own Authorship, Cachoeira, 2023.

DISCUSSION

The etymology of the term "ectopic teeth" is defined as "teeth out of position" and its etiology is still undefined and the therapeutic conduct may be different on a case-by-case basis.⁽⁶⁾

Most cases of ectopism are associated with dental clinical impaction, delayed eruption, non-dental eruption; which may be associated with functional changes; root resorption, formation of orthokeratinized dentiger and odontogenic cysts⁽¹⁾, or mechanism of intraosseous dental migration, the latter not being fully understood, however there are theories that mention the process of development of the jaw branch. According to the stretching of the branch, the dental germ can follow this movement and thus change its position.⁽³⁾

Seeking to understand this topic, Souza (2020) conducted a survey with 200 patients aged 16 to 30 years, that the positions with the highest degree of incidence for the third molars are: vertical (66.7%), mesioangular (24.3%), distoangular (5.4%), horizontal (3.5%), inverted (0.2%) and ectopic (0.0%)(2). The prevalence rate of retained molars can vary according to gender and can be 15.6% for women and 11.8% for men. However, Pinheiro and Aguiar (2021) point out that about 1% to 3% of the population has a third molar in an ectopic region, the second tooth that has this characteristic are the upper canines and its prevalence index is associated with genetic factors.

For the diagnosis of this dental anomaly, clinical, radiographic and/or imaging evaluation are considered crucial steps for adequate surgical planning, because with radiographic evaluation we can observe the dental position in relation to noble structures. There are two most used techniques: Radiography (2D) and Computed Tomography (3D). Two-dimensional (2D) images have some disadvantages when compared to computed tomography, taking as an example the image overlay. The tomography used can be fan beam or cone beam, so it can be used for maxillomandibular panoramic reconstruction, and used for the visualization of overlapping images delivered by the panoramic radiographic examination.⁽⁴⁾

Both techniques were used for the planning of this report. Thus, the panoramic x-ray was

used for the visualization and classification of units 47 and 48. Unit 48 was classified as impacted mesioangular, thus being B-I according to Pell & Gregory. Element 47, on the other hand, was retained in an ectopic position in the mandibular body region. Then, the association of the x-ray with the conebeam computed tomography was performed, which made it possible to perform the appropriate surgical planning for the case in question, and thus minimized the possible complications in the transsurgical procedure, because the tomography showed signs suggestive of an intimate relationship of the roots of the 47 with the lower alveolar nerve (IAI), and may promote possible post-surgical complications, namely: paresthesia, hemorrhage or even the injury of the adjacent tissues.

Intercomplications in the transsurgical process of lower molars with an advanced degree of impaction may be associated with complications that can be: injury to adjacent teeth, mandibular fractures, bone loss and injury or injury to the NAI. Another factor to be taken into consideration is the performance of osteotomies to remove the bone cortical in included teeth, which have a 2 times greater chance of causing a mandibular fracture.⁽¹³⁾

Based on the above assumption, in the case reported in this research, odontosection and osteotomy modified with the surgical piezoelectric was performed, because the piezo has some advantages when compared to conventional surgical milling cutters. Its applicability is associated with surgeries of lateralization of the NAI, lifting of the maxillary sinus and correction of dentofacial deformities because the piezo can promote protection of noble structures such as nerves and blood vessels⁽¹⁴⁾.

The piezo has some characteristics such as the "selective cut" that is performed O through ultrasonic vibration of the piezo tip, which generates a cavitation effect that acts on mineralized tissues and thus promotes bone tissue rupture generating the cut. In this way, the making of thinner cuts with greater stability is made possible, minimizing bleeding in the transsurgical process, enabling a better visualization of the surgical store.^(5,10)

In order to fill the surgical store, two types of grafts were used: xenogen and autogenic. The autogen was harvested at the time of the modified osteotomy and immersed in physiological serum so as not to dehydrate. At the end, the stabilization of the autogenous graft was done with the help of a titanium plate and screws and covered with collagen membrane (BIOGLIDE®). Collagen membranes must have biocompatibility and their characteristic is to prevent soft tissue cell migrations and bacterial infections. Its action happens in an occlusive way and its barrier function is maintained until there is a bone neoformation being widely used in ROG due to its properties.⁽²²⁾

These materials are used in association with ROG techniques that follow the principle of Guided Tissue Regeneration, where the cells populate the injured site in its healing process. Thus, it is a mechanical barrier that generates the exclusion of soft tissue and thus allowing the

proliferation of cells that will give rise to bone tissue. This technique is indicated for increasing the height and thickness of the alveolar edge. Some edge maintenance techniques have been evaluated, having excellent results such as the association of xenogen graft with collagen membranes, the brands with the best results were (BIOOSS®) and (BIOGLIDE®). The use of these materials has advantages when compared to the others, as it does not require a donor area for the removal and relocation of autogenous materials⁽²¹⁾. For this reason, these were the brands used in this case.

There are several ways to acquire autogenous grafts: the most common are iliac crest, rib, skullcap, jaw and tibia. This bone tissue has a surprising characteristic of regeneration and repair. However, the recovery process is long and arduous for the patient.⁽¹⁶⁾

Grafts made from materials of biological origin must be biocompatible, non-toxic, non-carcinogenic and non-radioactive to be effective. According to the literature, the autogenous graft has a proven efficacy, and a superior compatibility to xenogenic biological material, and in treatment, it is considered the gold standard for eliminating the problem of compatibility and disease transmission. In addition, they are the only type that can provide live bone cells and immuno compatible with their receptor.^(12,16,17).

Xenogenic grafts come from one animal species that is transplanted to another. The most used are lyophilized bovine grafts, since due to the lyophilization process there is a lower possibility of rejection because there is a large decrease in their antigens, which also reduces the risk of contamination. When the xenogen graft is used, it is not necessary to perform a second surgical site for the removal of donor material, as is done with autogenous graft. The combination of the two techniques allows greater stability and has a lower rate of bone volume loss in the postoperative period.⁽¹⁷⁻²⁰⁾

The postoperative process for surgeries performed with surgical piezoelectric have greater comfort to the patient, significant reduction of the edematous process, and reduction of painful symptoms⁽¹⁴⁾. In the reported case, there were no complications in the post-surgical process beyond what was expected, such as controlled edema, trismus and paresthesia, which according to the patient lasted only one week.

CONCLUSION

Ectopic teeth are uncommon and of uncertain origin, the vast majority are discovered through routine examinations when imaging tests such as periapical or panoramic radiography are performed. The conduct for the resolution of this problem may vary because each case is unique. When surgical removal is chosen, it is necessary to have a very well elaborated planning and the request of imaging tests to avoid possible damage to the patient in the trans and post-surgical

process. In the reported case, the performance of the modified osteotomy made it possible to reuse the bone window, which in the conventional technique would be milled and could lead to a mandibular fracture. We then concluded that individualized planning and the use of modern techniques enabled a better prognosis for the case. Ectopic teeth are uncommon and of uncertain origin, the vast majority are discovered through routine examinations when imaging tests such as periapical or panoramic radiography are performed. The conduct for the resolution of this problem may vary because each case is unique. When surgical removal is chosen, it is necessary to have a very well elaborated planning and the request of imaging tests to avoid possible damage to the patient in the trans and post-surgical process. In the reported case, the performance of the modified osteotomy made it possible to reuse the bone window, which in the conventional technique would be milled and could lead to a mandibular fracture. We then concluded that individualized planning and the use of modern techniques enabled a better prognosis for the case.

REFERENCES

1. Siles ERA, Fernandes FS, Brito RS, Pinchemel ENB. Erupção dentária ectópica e o impacto sobre a cavidade oral: Revisão de literatura. Id on Line Rev. Mult. Psic. [Internet]. 2020;14(50):1231–8. Disponível em: <https://idonline.emnuvens.com.br/id/article/view/2531>. Acesso em: 24 mar 2025.
2. Souza C. Complicações cirúrgicas de terceiro molar em posição ectópica: Revisão de literatura [Trabalho de Conclusão de Curso - UNITAU]. Taubaté: Universidade de Taubaté; 2020. Disponível em: <http://repositorio.unitau.br/jspui/handle/20.500.11874/3811>. Acesso em: 24 mar 2025.
3. Dias AM, Martins BV, Júnior FJS, Guedes LJA, Kataoka MSS. Terceiro molar ectópico em côndilo associado a cisto dentígero: Um relato de caso. RDAPO [Internet]. 2018;2(1):4-8. Disponível em: <https://apopara.com.br/revista/index.php/apo/article/view/44>. Acesso em: 24 mar 2025.
4. Bomeisel MS, Ribeiro E, Palazzi AAA, Tognetti VM. Fraturas mandibulares decorrentes da exodontia de terceiros molares inclusos - Revisão de literatura. RECISATEC [Internet]. 2022;2(12):e212224. Disponível em: <https://recisatec.com.br/index.php/recisatec/article/view/224>. Acesso em: 24 mar 2025.
5. Rocha LLA, Rodrigues MFB, Barbosa IMG, Acyoli RF, Carvalho DC, Souza DD. Exodontia atraumática por meio da piezocirurgia em tratamento de erupção ectópica em seio maxilar: Relato de caso. Arch Health Invest [Internet]. 2021; 10(6):851-4. Disponível em: <https://www.archhealthinvestigation.com.br/ArcHI/article/view/5308>. Acesso em: 24 mar 2025.
6. Ishii JTR, Batista JD, Gondo RM, Melo PEC, Silva CM, Rocha FS. Terceiro Molar Ectópico em Incisura Mandibular. Med [Internet]. 2022; 55(2):e-188343. Disponível em: <https://www.revistas.usp.br/rmrp/article/view/188343>. Acesso em:
7. Barros JFA, Dias LLR, Foester RB, Filgueiras PS. Análise da prevalência de anomalias dentárias: Uma revisão de literatura. RANM. 2021;3(4):1-10. Disponível em: <chrome-extension://efaidnbmnnnibpcajpcglclefindmkaj/https://novomilenio.br/wp->

content/uploads/2021/07/Analise_da_prevalencia_de_anomalias_dentarias-uma_revisao_de_literatura.pdf. Acesso em: 24 mar 2025.

8. Pinheiro VB, Aguiar FM. Exodontia de canino ectópico em região maxilar: Relato de caso. Braz J. Develop [Internet]. 2021;7(11):102617–28. Disponível em: <https://ojs.brazilianjournals.com.br/ojs/index.php/BRJD/article/view/39061>. Acesso em: 24 mar 2025.

9. Botelho TCA, Dantas ACO, Pimentel SMA, Corrêa AKM. Acidentes e complicações associados à exodontia de terceiro molar inferior impactado: Revisão de literatura. Braz. J. Develop [Internet]. 2020;6(12):96918-31. Disponível em: <https://ojs.brazilianjournals.com.br/ojs/index.php/BRJD/article/view/21393>. Acesso em: 24 mar 2025.

10. Carvalho MAL, Marques G, Trento GS, Padovan LEM, Klüppel LE. Utilização do sistema piezoelétrico em cirurgias bucais: Indicações, vantagens e desvantagens. J Dent Pub H [Internet]. 2017;8(1):13-8. Disponível em: <https://www5.bahiana.edu.br/index.php/odontologia/article/view/1000>. Acesso em: 24 mar 2025.

11. Macedo DV. Análise por meio de elementos finitos, de enxertos ósseos, associados à placas de reconstrução em defeitos mandibulares [Tese de doutorado na internet]. Araraquara: Universidade Estadual Paulista UNESP-FOAR; 2022. p. 75. Disponível em: <http://hdl.handle.net/11449/237098>. Acesso em: 24 mar 2025.

12. Marcone E, Thainara J, Schimassek R, Neder VM. Enxertos e membranas na odontologia: Revisão da literatura. 2020;10(1):6-14. Disponível em: <https://revistas.brazcubas.br/index.php/roubc/article/view/990>. Acesso em: 24 mar 2025.

13. Segundo AVL, Nogueira EFC, Nascimento DF, Silva LNB, Silva PA. Osteotomia sagital do ramo mandibular na remoção de dentes impactados: Relato de caso. Rev. Cir Traumatol Buco_maxilo-Fac. 2017;17(3):21-4. Disponível em: <chrome-extension://efaidnbmnnnibpcajpcglclefindmkaj/https://www.revistacirurgiabmf.com/2017/03/Artigos/05ArtcasoclinicoOsteotomiasagitaldoramopdf>. Acesso em: 24 mar 2025.

14. Frare JG. Ensaio clínico randomizado e cruzado entre a piezocirurgia e a técnica convencional rotatória para a exodontia de terceiros molares inferiores [Dissertação de Mestrado na Internet]. São Paulo: Universidade de São Paulo; 2018. p. 84. Disponível em: <https://repositorio.usp.br/item/002940193>. Acesso em: 24 mar 2025.

15. Miranda MC, Hartmann I. O Uso de biomateriais para reparo ósseo na odontologia: Uma revisão de literatura. Braz. J. Develop [Internet]. 2022;8(1):3726–36. Disponível em: <https://ojs.brazilianjournals.com.br/ojs/index.php/BRJD/article/view/42701>. Acesso em: 24 mar 2025.

16. Ribeiro RR, Pinheiro DA. Escolha de materiais de enxerto ósseo na reabilitação oral [Trabalho de Conclusão de Curso]. Rio Verde: Universidade de Rio Verde – UNIRV; 2020. p. 14. Disponível em: <https://www.unirv.edu.br/conteudos/fckfiles/files/RODRIGO%20RIBEIRO%20SILVA.pdf>. Acesso em: 24 mar 2025.

17. Cardoso B, Keruak JAH, Cardoso PH, Nascimento FD, Vasconcelos F. Comparativos entre enxertos autógenos, heterógenos, hidroxiapatita e quitosana em fêmur de ratos. Rev. UMC. 2021;6(2):1-4. Disponível em: <https://seer.umc.br/index.php/revistaumc/article/download/1678/1084/5798>. Acesso em: 24 mar 2025.

18. Claudino J, Alves LAC. Biomateriais: Uma realidade para as cirurgias de enxerto em odontologia - Revisão da literatura. *J Health Sci Inst.* 2019;37(2):174–7. Disponível em: https://repositorio.unip.br/wp-content/uploads/2020/12/13V37_n2_2019_p174a177.pdf. Acesso em: 24 mar 2025.
19. Santos BN, Nepomuceno AKTS, Trinta LB, Flor LCS, Pereira MHT, Diniz NS, et al. O Uso de enxerto xenógeno associado à fibrina rica em plaqueta no tratamento de fraturas faciais: Uma revisão de literatura. *E-Acad.* 2022;3(3):e0533265. Disponível em: <https://eacademica.org/eacademica/article/view/265/217>. Acesso em: 24 mar 2025.
20. Pedroso FHF, Leal MSS. Tratamento regenerativo da perimplantite com a associação de l-prf e enxerto bovino liofilizado - Revisão de literatura [Trabalho de Conclusão de Curso]. São Paulo: Universidade São Judas Tadeu; 2021. p. 40. Disponível em: <https://repositorio.animaeducacao.com.br/items/9adb75bd-f8db-47a9-95fb-1652050d03ea/full>. Acesso em: 24 mar 2025.
21. Ayub LG, Novaes AB Júnior, Grisi MFM, Taba M Júnior, Palioto DB, Souza SLS. Regeneração óssea guiada e suas aplicações terapêuticas. *Periodontia.* 2011;21(4):24-31. Disponível em: <https://pesquisa.bvsalud.org/portal/resource/pt/lil-642416>. Acesso em: 24 mar 2025.
22. Pilger AD, Schneider LE, Silva GM, Schneider KCC, Smidt R. Membranas e barreiras para regeneração óssea guiada. *Ver Ciênc Méd Biol.* 2020;19(3):441-8. Disponível em: <chrome-extension://efaidnbmnnnibpcajpcgclefindmkaj/https://docs.bvsalud.org/biblioref/2022/02/1357945/36390-texto-do-artigo-163925-1-10-20201215.pdf>. Acesso em: 24 mar 2025.